

Report on the outcomes of a Short-Term Scientific Mission¹

Action number: CA18221

Grantee name: Gledjan Caka

Details of the STSM

Title: Histochemical and immunohistochemical techniques on amphibians' tissues

Start and end date: 05/09/2022 to 07/10/2022

Description of the work carried out during the STSM

Description of the activities carried out during the STSM. Any deviations from the initial working plan shall also be described in this section.

(max. 500 words)

The samples were fixed in neutral buffered formalin 10% in 1,5ml tubes at 4°C. The tadpoles were separated by their corresponding groups: control, 5ug/l and 25ug/l CuSO₄ treatment. The first step was to put all the samples in containers filled with PBS for 15 minutes (x2) and 10 minutes in distilled water for the washing process. Then, the samples are put through a dehydration process, by passing the samples in raising percentages of ethanol (50% - 3 hours, 80% - 4 hours, 95% - 3,5, 100% - 3). Finished the dehydration step, the samples were clarified with xylene for 3 hours: this step helps by substitute alcohol with xylene, in order to proceed with the infiltration/paraffinization process. Hence, the samples are put in a solution with a 50%-50% composition of xylol and paraffin overnight at temperature of 60°C. The following day the samples are removed from this solution and put in containers filled with melted paraffin (kept at 60°C in order to not solidify) to conclude the infiltration process. This process is followed by placing the tadpoles with the belly side facing down in moulding blocks and pouring melted paraffin on top of them and letting it cool down. The blocks are then carefully trimmed in order to remove the protective paraffin and to expose the tissue surface to the level where a representative section can be cut. The paraffin blocks are then sliced with a microtome and cut sections with a 5um thickness were prepared (the first few sections of the samples were discarded as to avoid imperfections by the trimming process). The sliced sections were put in a water bath of 45°C (helps by straightening the paraffin slices) and then laid on glass slides layered with a mixture of albumin and butter to help the slices stick better. Afterwards the glass slides are put in the oven overnight at 37°C. This process helps the paraffin strips

¹ This report is submitted by the grantee to the Action MC for approval and for claiming payment of the awarded grant. The Grant Awarding Coordinator coordinates the evaluation of this report on behalf of the Action MC and instructs the GH for payment of the Grant.

to adhere to the slides better and not be removed during the next phases and also straightens the slices even further so that the images will be clearer.

After the embedding and slide preparation stage, the samples are then stained so that they can be examined with the microscope. The first protocol we followed was the haematoxylin-eosin (H&E) staining. The samples which were put in the oven overnight are put through the hydration process which is as follows:

15 minutes in xylene

5 minutes respectively for ethanol 100%, 95%, 80%, 50%, distilled H₂O.

After the hydration phase, the slides are put in haematoxylin for 10 minutes, then washed with running water for another 10 minutes. The slides are positioned in eosin for 10 more minutes, then quickly rinsed in distilled water and transferred to ethanol 95%, 100% and finally xylol for 5 minutes each. After removing them from the xylol the samples are fixed with a balsam glue with a xylol composition then fitted with another glass slide on top of them.

Another staining method we did, was the periodic acid Schiff (PAS) procedure. The hydration process is the same as the H&E phase. After this process, the samples are put in periodic acid 1% for 5 minutes, then washed with distilled water for 10 minutes. The samples are immersed in the PAS solution for 30 minutes, and afterwards in sulphuric water for a couple of mins. Then the slides undergo the dehydration process again and, in the end, fixed with the balsam glue ready to be examined in the microscope.

Once the whole staining protocol is finished, the slides are observed under an optical microscope and picture taken with a camera.

Description of the STSM main achievements and planned follow-up activities

Description and assessment of whether the STSM achieved its planned goals and expected outcomes, including specific contribution to Action objective and deliverables, or publications resulting from the STSM. Agreed plans for future follow-up collaborations shall also be described in this section.

(max. 500 words)

80 *Bufo bufo* tadpoles divided in 4 experimental groups comprised of 20 individuals each in the home institution of the STSM grantee: (1) control; (2) treated with 5ug/l copper sulphate; (3) 25ug/l and (4) 100 ug/l. No deaths were observed among the control and groups two and three, whereas all the individuals from group four died because of the high concentration. From each group (apart the 4th), 5 individuals were used to obtain blood samples by cardiac puncture. A total of 1000 erythrocytes from each tadpole was evaluated. The MNA frequency was expressed per 1000 cells counted and the. The results showed that the erythrocytes of the treated bufotes displayed a number of morphological malformations such as swollen, karyorrhectic and pycnotic erythrocytes. The severity of these abnormalities was directly linked to the increasing concentration of copper sulphate. No anomalies were observed within the control group during the experiment days. In contrast, some degree of edema was seen in the highest concentration group, as well as in the samples treated with 25ug/l CuSO₄. Histological longitudinal sections support the results that the control group had no morphological anomalies present as observed on the cut sections for the medulla oblongata, notochord, liver, stomach, and kidneys. On the other hand, the CuSO₄ treated groups showed an increasing number of organ deformities. No histological anomalies were shown in the liver of the control tadpoles. However, we observed a loss of shape and form of the liver in the longitudinal section (note that it could be biased from the cutting surface and orientation of the organ) of the 5ug/l group and this deformity was even more exacerbated in the 25ug/l *Bufo bufo*. At histomorphological level, degradation of the hepatocytes and an increase of the intercellular areas was visible in the treated groups as low as 5ug/l. Apart from the liver, an examination was performed on the kidney tissues too. The pronephric tubules of the untreated tadpoles showed no abnormal histopathological findings. We found epithelial deformations of the tubules in the lowest doses, which

were more obvious in the 25ug/l dose. Loss of tubule density was seen gradually raising with the treatment.

This STSM achieved its primary objective of doing histological examinations on *Bufo bufo* tissues and also achieving new results that even on lower concentrations (5ug/l and 25ug/l) of CuSO₄, the damage done to these organisms is quite high. The effects of copper sulphate as a pesticide may seriously affect populations of *B. bufo* tadpoles by severely decreasing them. Our results show that a histological approach is necessary to examine morphological inner abnormalities in the larval stages of amphibians. All these changes lead to different deformities depending on the level of toxic exposure to CuSO₄. The deformities we focused on affect the liver and kidneys, leading to a poor development of the organism and to low life expectancy and high mortality.

Our groups may follow up with these experiments in the future, in order to analyse the collected samples by doing another series of histological and histochemical assays to check if there are other anomalies we may find in different tissues or cells. One approach is to assess cellular and subcellular compartments via digital image analysis. Another approach may be to further lower the CuSO₄ concentrations in order to evaluate the effects and compare the results with the ones we already have.

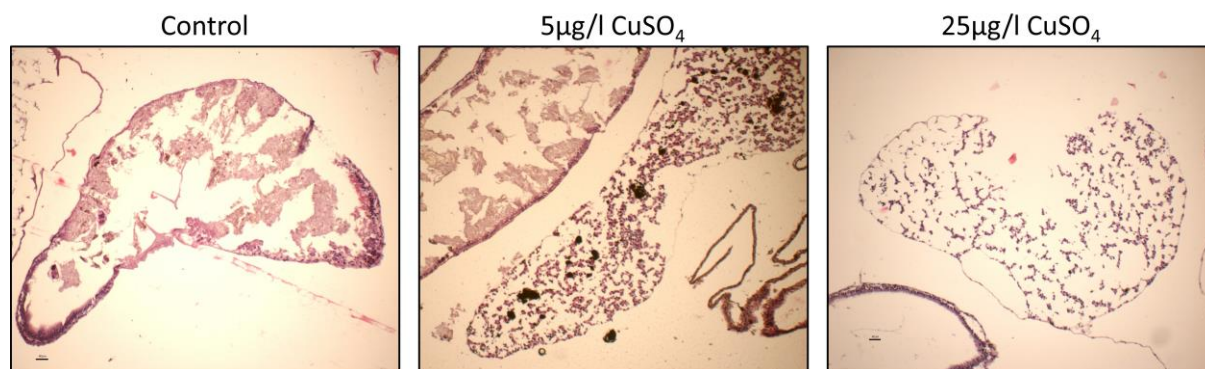


Figure 1: Liver seen in longitudinal sections show clustering of the hepatocytes. With the increase of the dose, the tissue is more deformed. Deformations of the structure are clearly seen in the 5µg/l CuSO₄ and 25µg/l CuSO₄

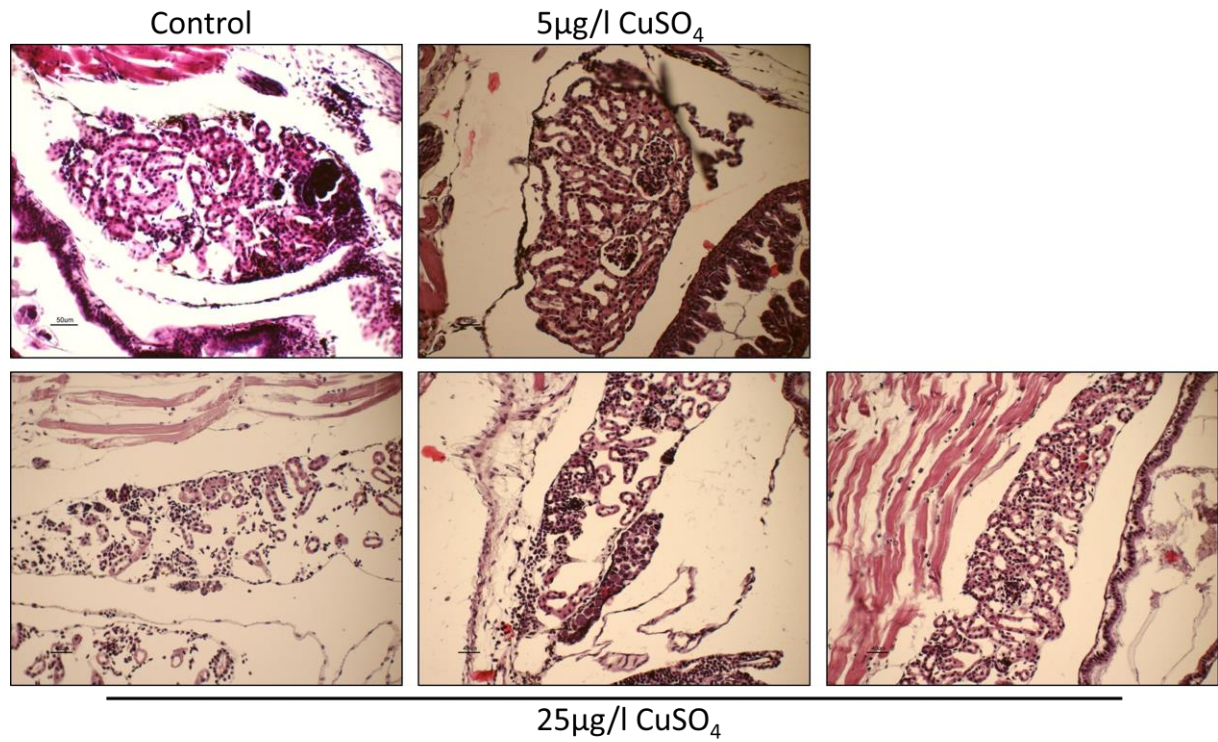


Figure 2: Kidneys seen in longitudinal sections show pronephric tubules and also cellular disorganization comprising oedemas. At the same time, we see that the epithelial layer of the tubules shows deformations (marked with arrows). The 5µg/l treatment show slight shape changes, but the 25µg/l dosage show significant structural deformations, as well as loss in tubule density accompanied with edema.